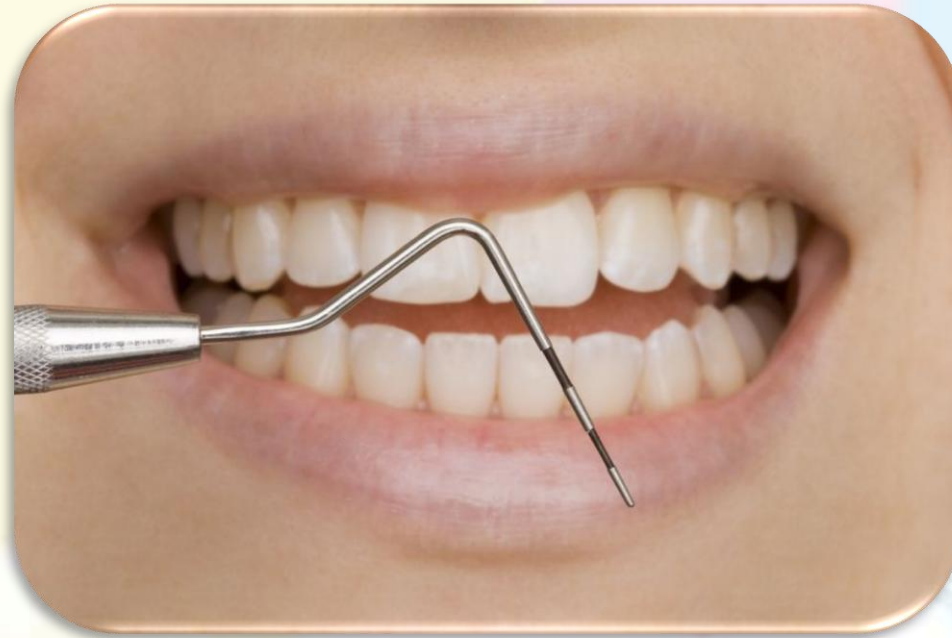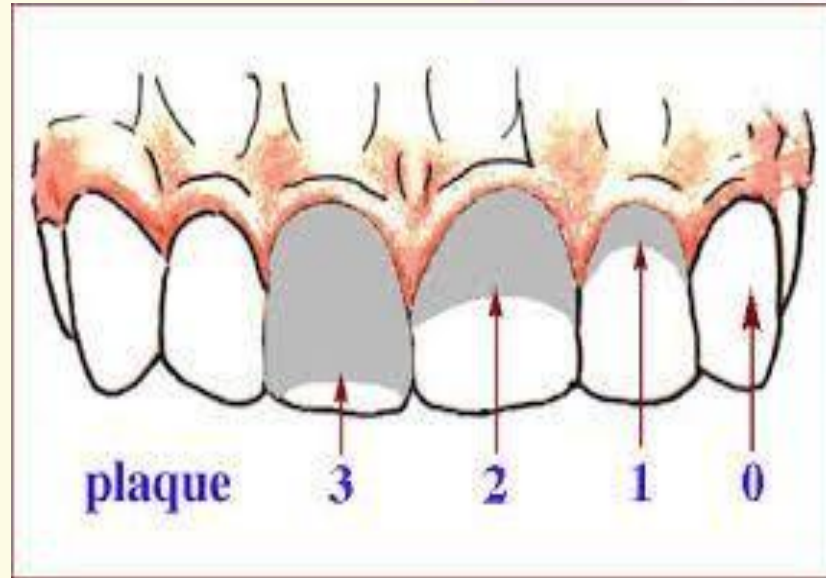


# Periodontal examination



# Plaque index



**0 = No plaque**

**1 = Plaque covering  $\leq 1/3$  of the tooth surface**

**2 = Plaque covering  $1/3$ - $2/3$  of the tooth surface**

**3 = Plaque covering  $\geq 2/3$  of the tooth surface**

**9 = Not recorded**

# Plaque index

ใส่ระดับ 0-3 ตามซี่ที่มี plaque มากที่สุดใน sextant นั้น

#55B	#51B	#65B
(Upper Right Posterior)	(Upper Anterior)	(Upper Left Posterior)
(Lower Right Posterior)	(Lower Anterior)	(Lower Left Posterior)
#85B	#71B	#75B

# Gingival bleeding score (modified)

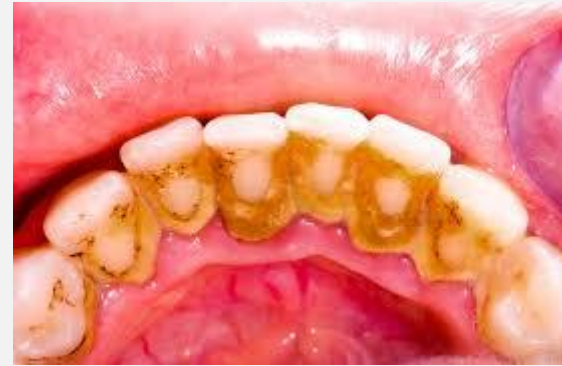**0 – Healthy**

**1 – Bleeding**

**2 – Calculus**

**5 – Calculus with bleeding**

**9 – Not recorded**



## Pocket score (modified)

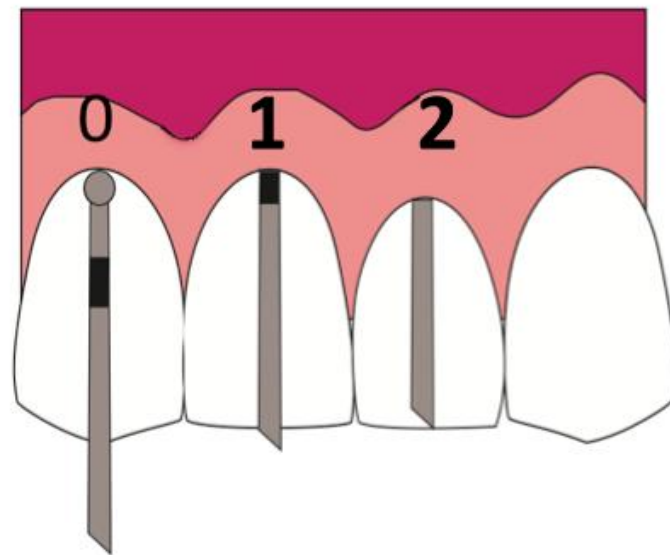
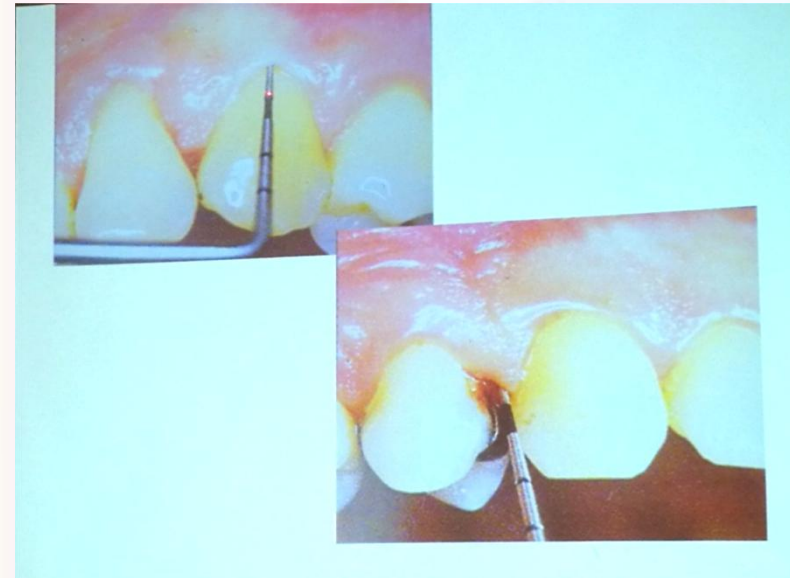
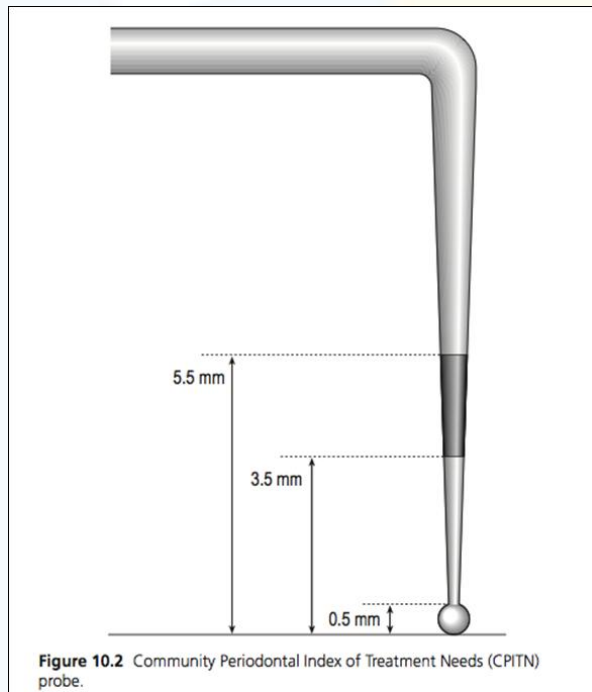
**0 – Absence of condition**

**1 – Pocket 4-5 mm**

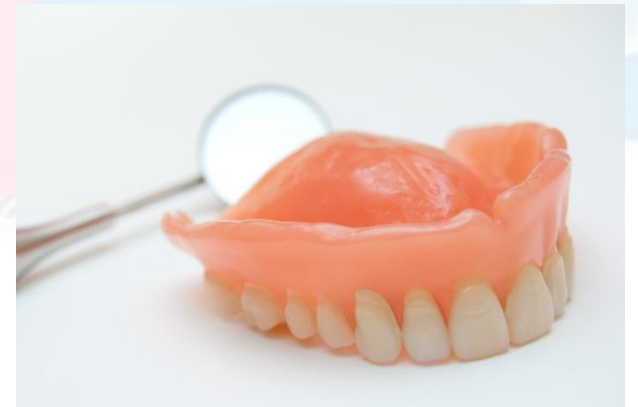**2 – Pocket 6 mm or more**

**9 – Not recorded**

# Pocket score (modified)



# **Prosthetic status and Prosthetic need**

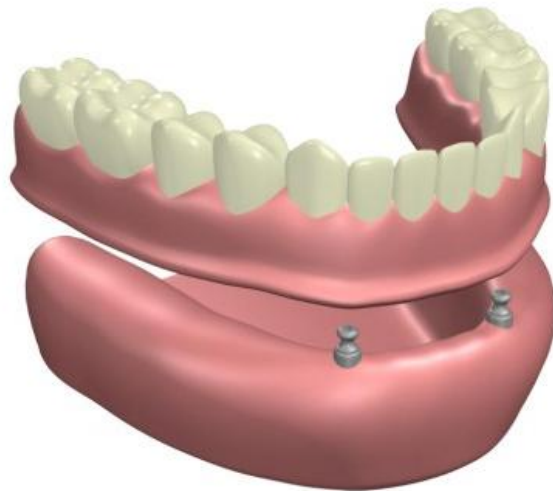
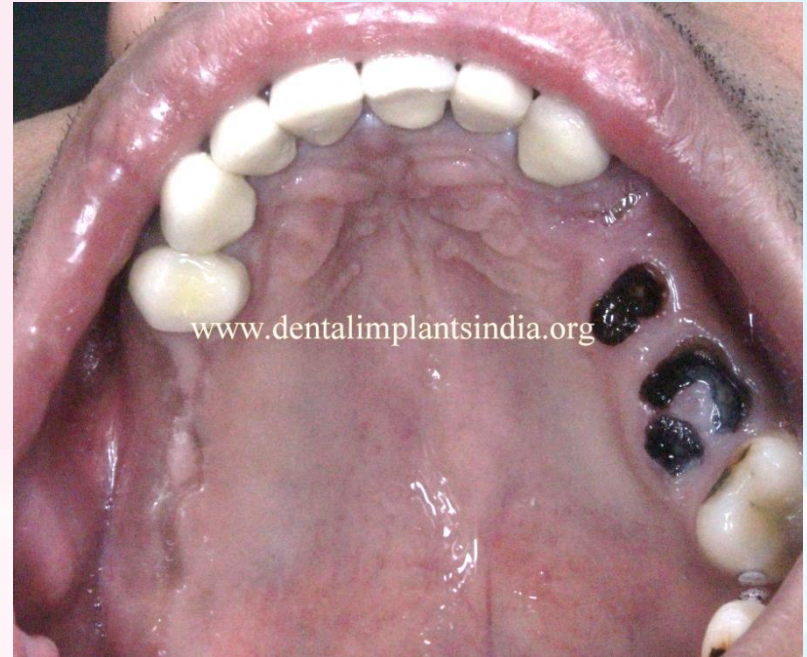
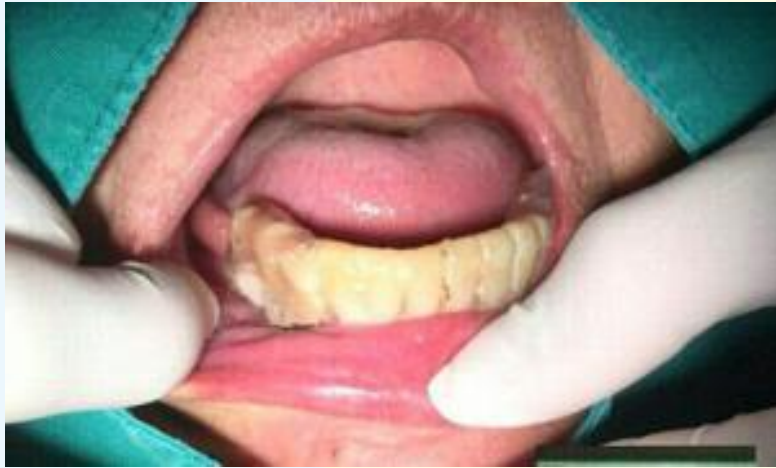
## Prosthodontic status

- 0 – No prosthesis**
- 1 – Bridge/Single implant**
- 2 – More than one bridge**
- 3 – Partial denture: TP PD**
- 4 – Both bridge/s and partial denture/s**
- 5 – Full removable denture**
- 6 – Coping with complete denture**
- 9 – Not recorded**



# Prosthetic status

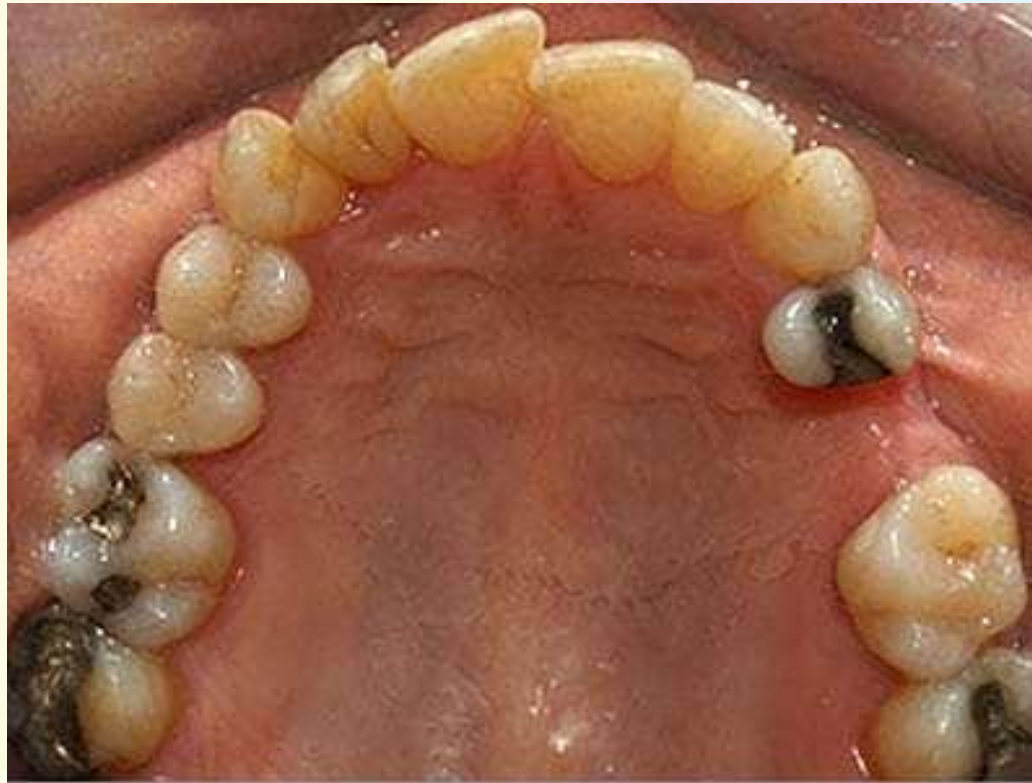


## Prosthodontic need

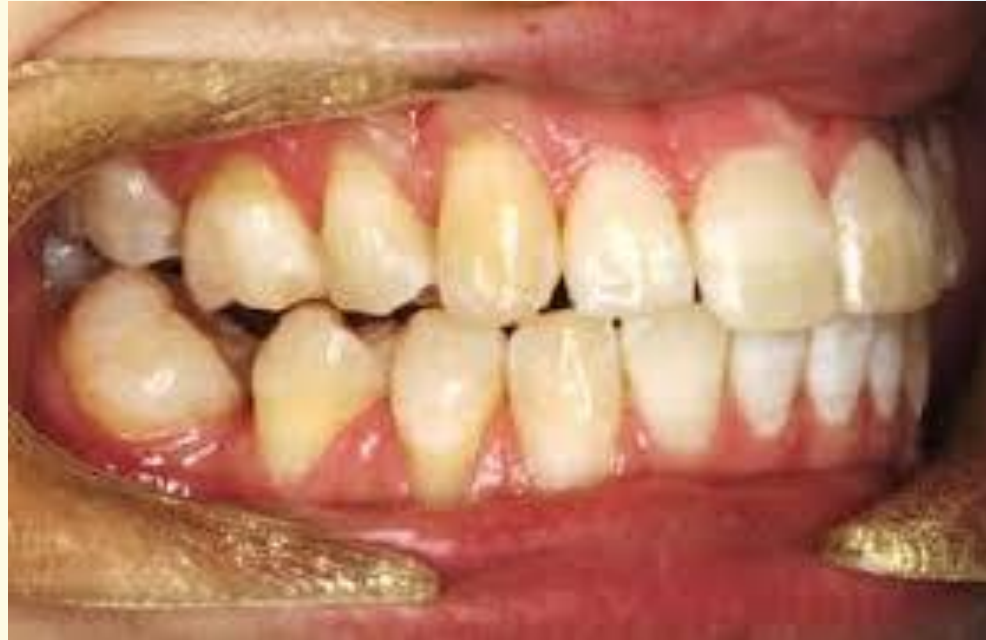- 0 – No prosthesis needed**
- 1 – Need for one-unit prosthesis**
- 2 – Need for multi-unit prosthesis**
- 3 – Need for full prosthesis**  
**(replacement of all teeth)**
- 4 – Need to repair denture**
- 9 – Not recorded**

**คิดแค่ 1 step**

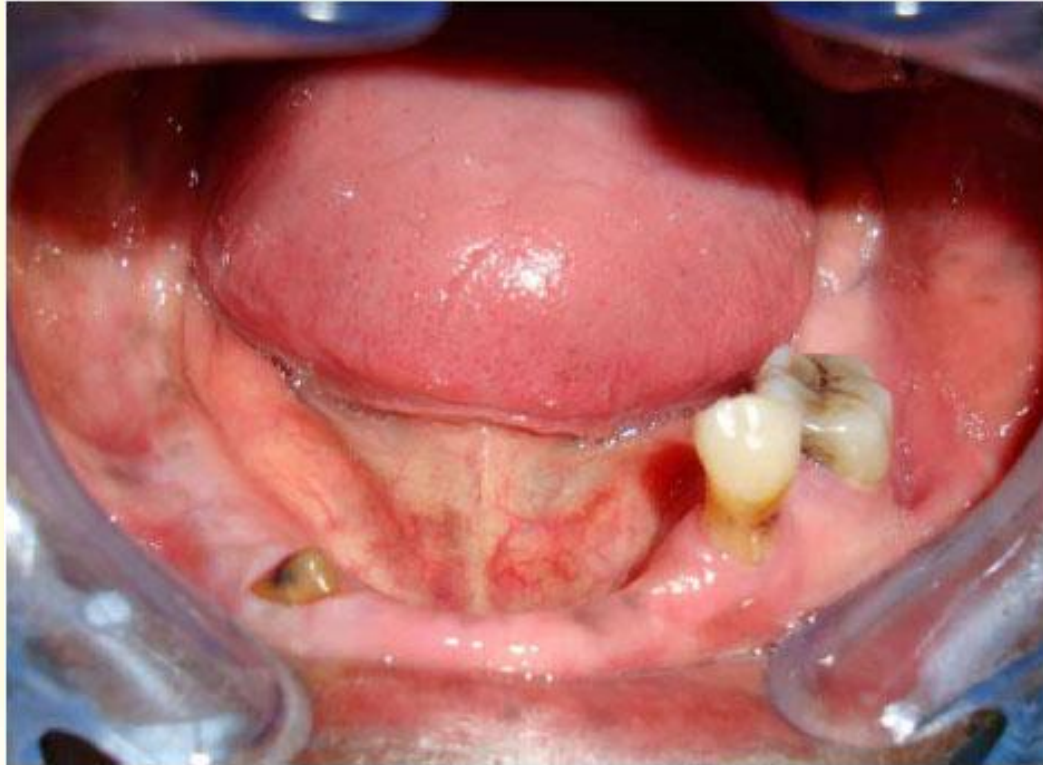# Prosthodontic need



# Prosthodontic need

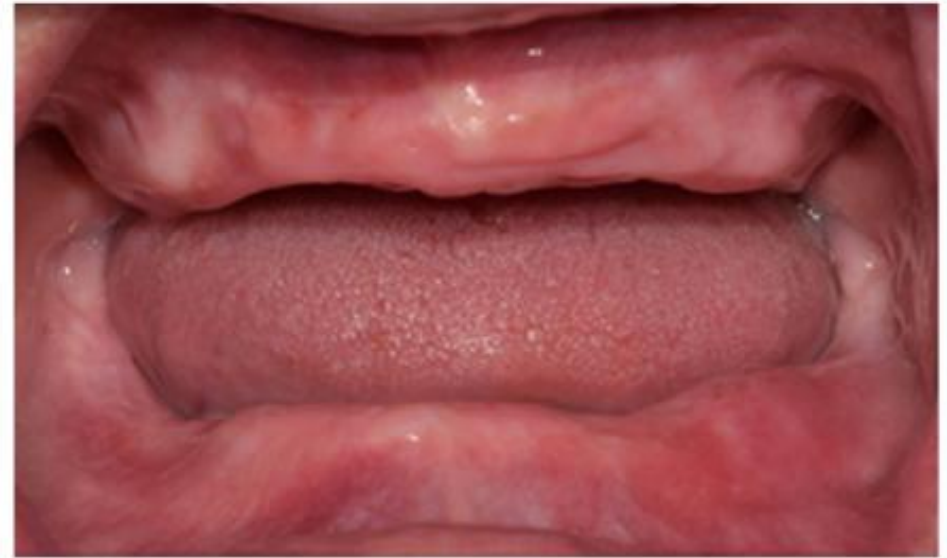
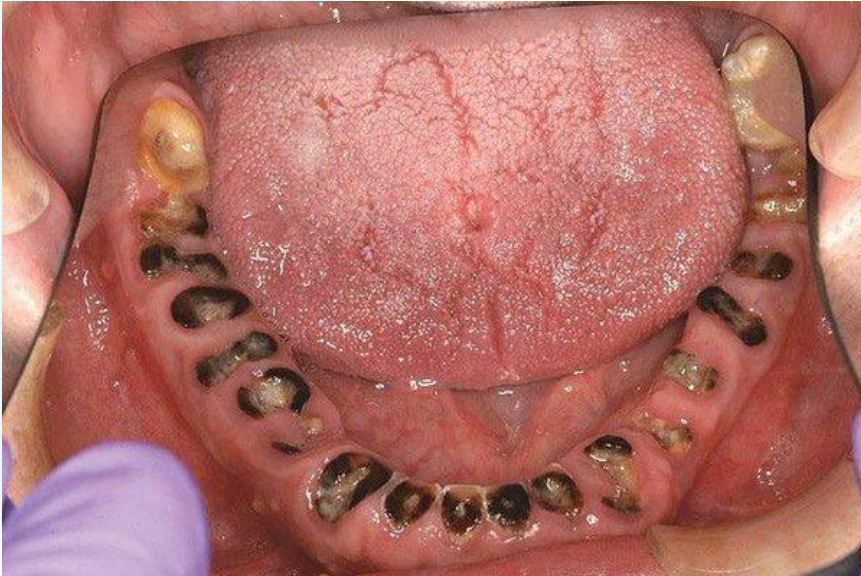
# Prosthodontic need





# Prosthodontic need



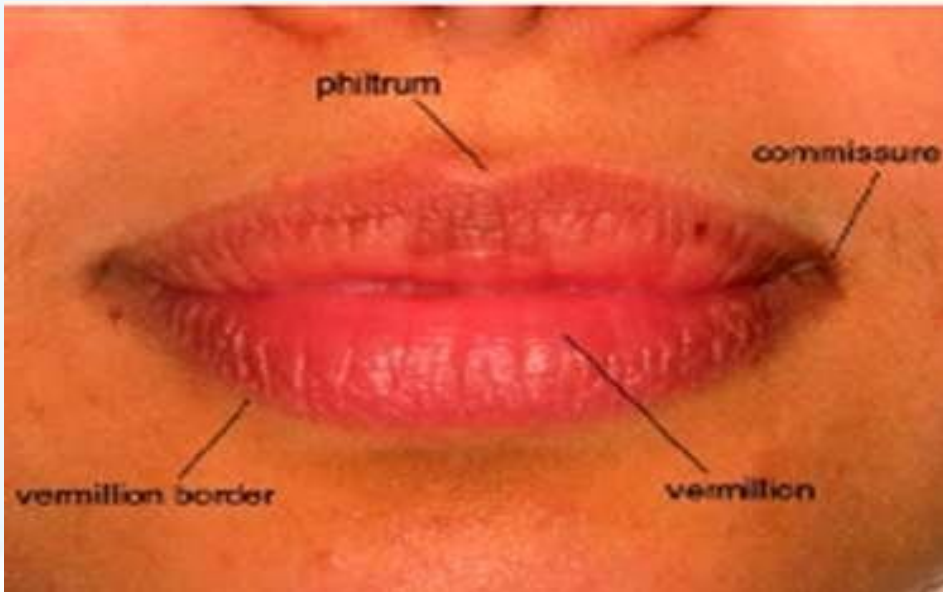
## Posterior occlusal pairs

- นับเฉพาะคู่สบฟันแท้
- นับตั้งแต่ first pre-molar ถึง third molar
- แยก ซ้ายและขวา
- ข้างละไม่เกิน 5 คู่

# Oral lesion



# Location



**V = ขอบริมฝีปาก (Vermillion border)**

**C = มุมปาก (Commissures)**

**L = ริมฝีปาก (Lips/vermillion)**

**S = ช่องระหว่างริมฝีปากหรือแก้ม กับเหงือก และฟัน (Sulci/vestibule)**

**B = เยื่อเมือกกระพุ้งแก้ม (Buccal mucosa)**

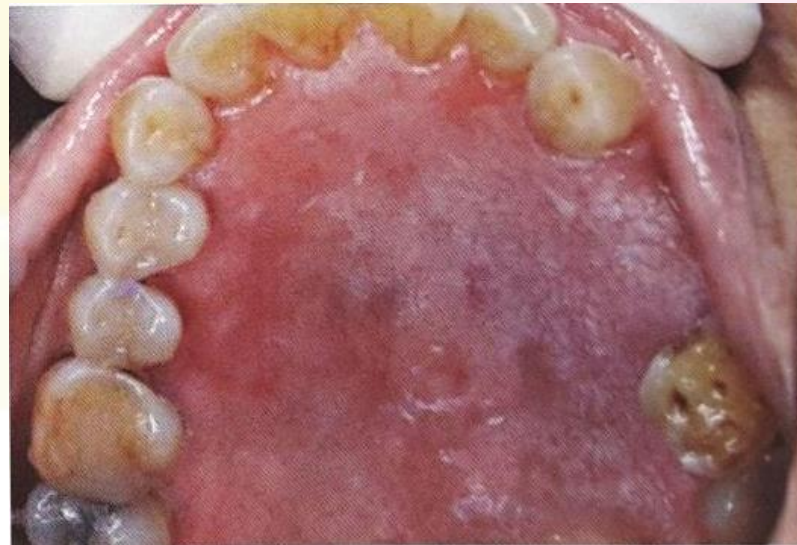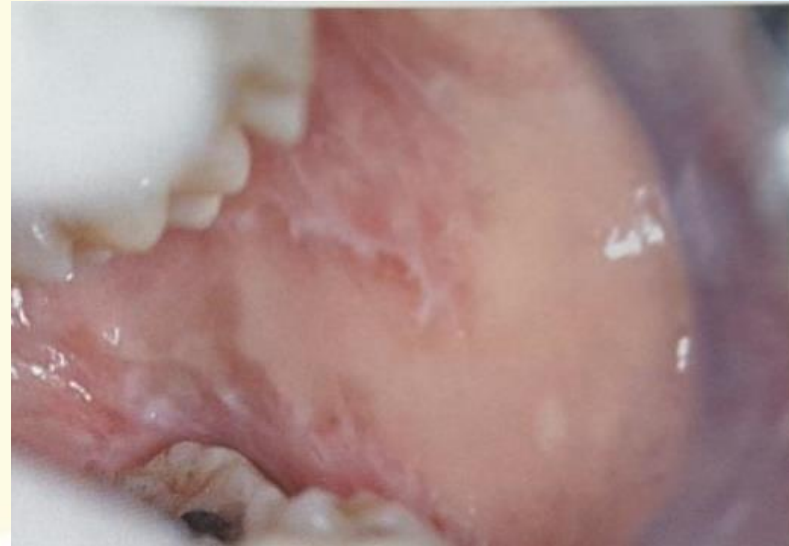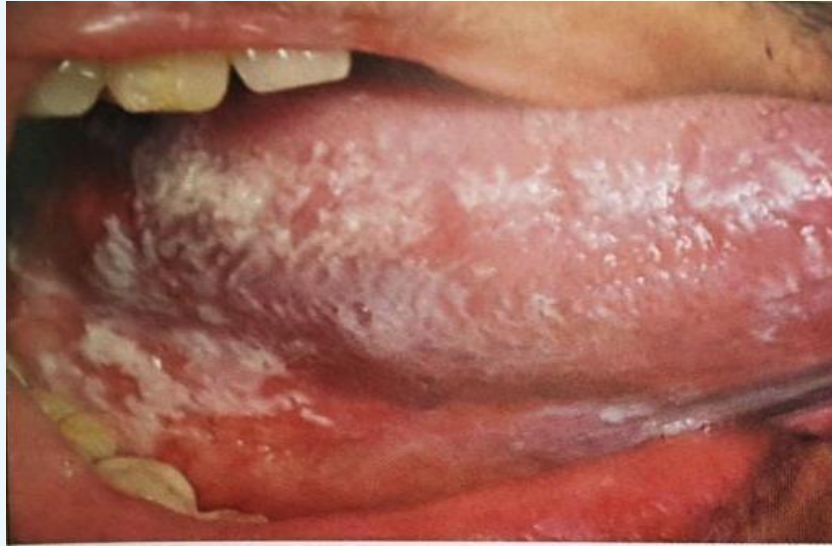
**F = พื้นช่องปาก (Floor of mouth)**

**T = ลิ้น (Tongue)**

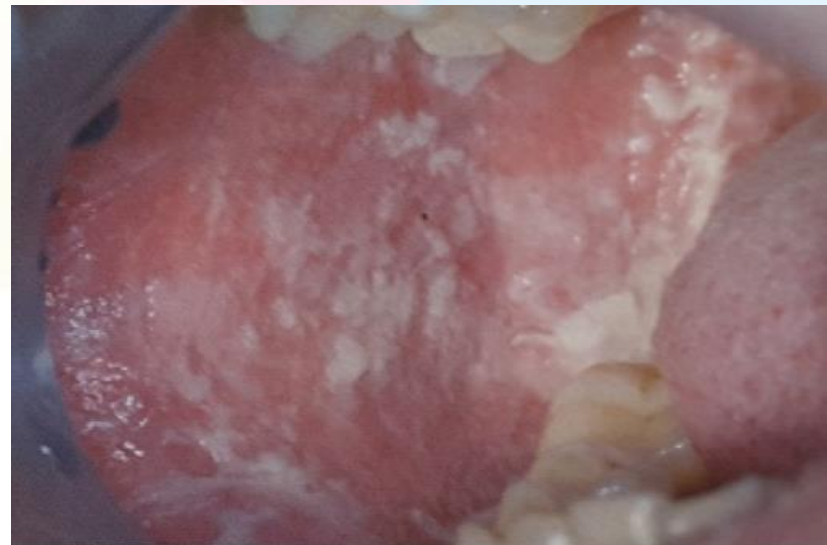
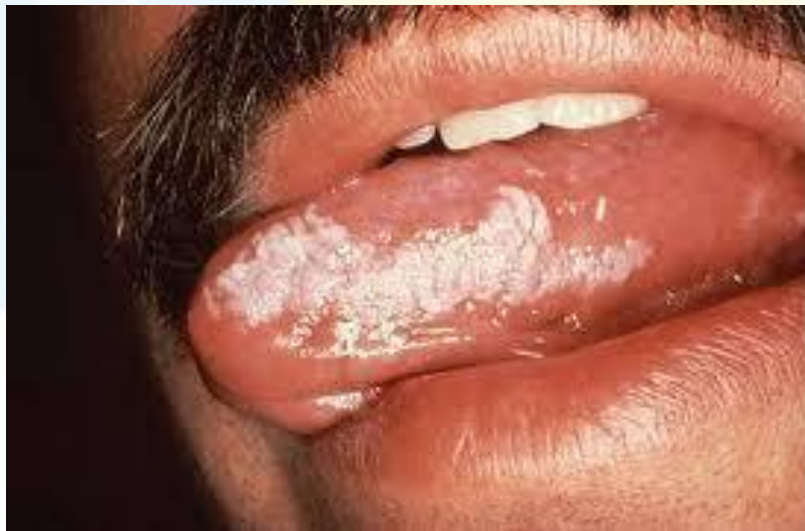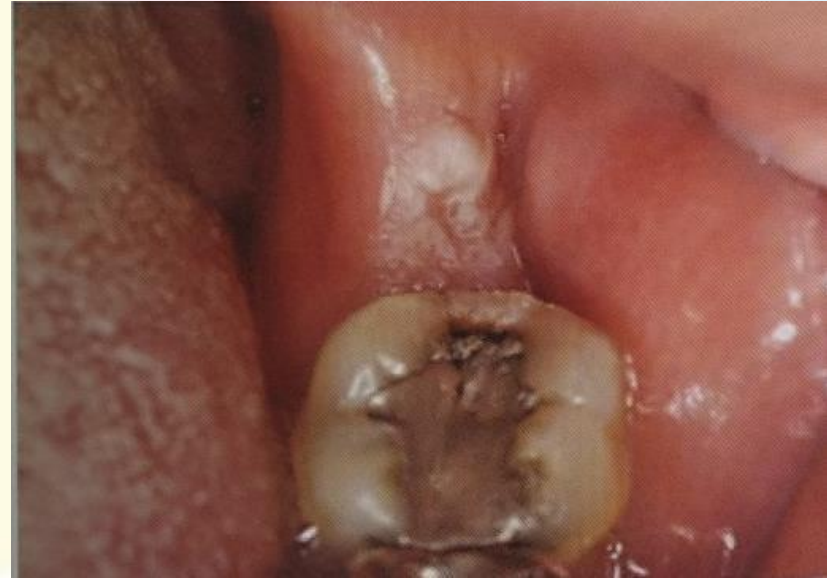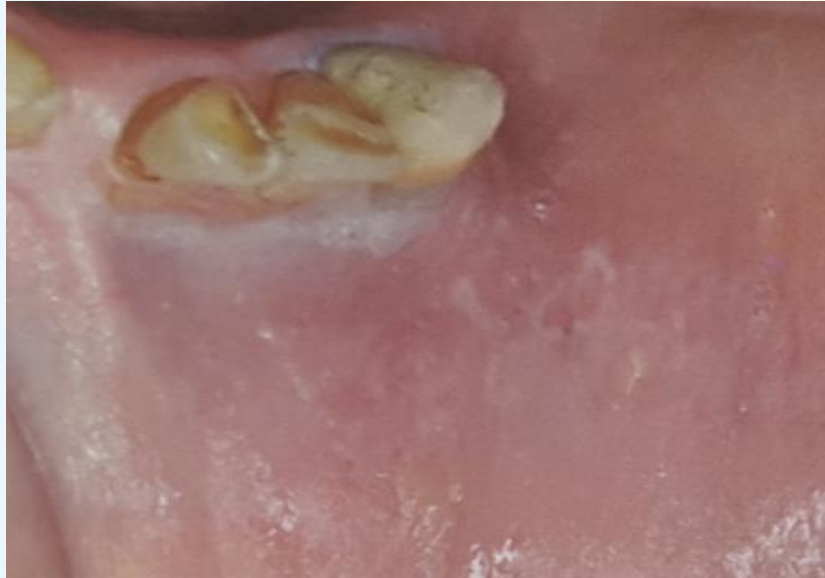**P = เพดานปาก (Hard / soft palate)**

**G = เหงือก (Alveolar ridges / gingiva)**

# White lesion

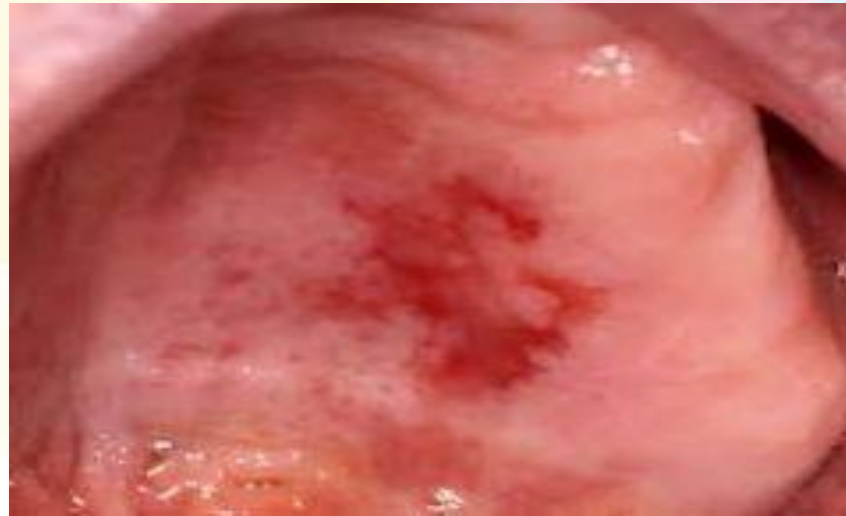
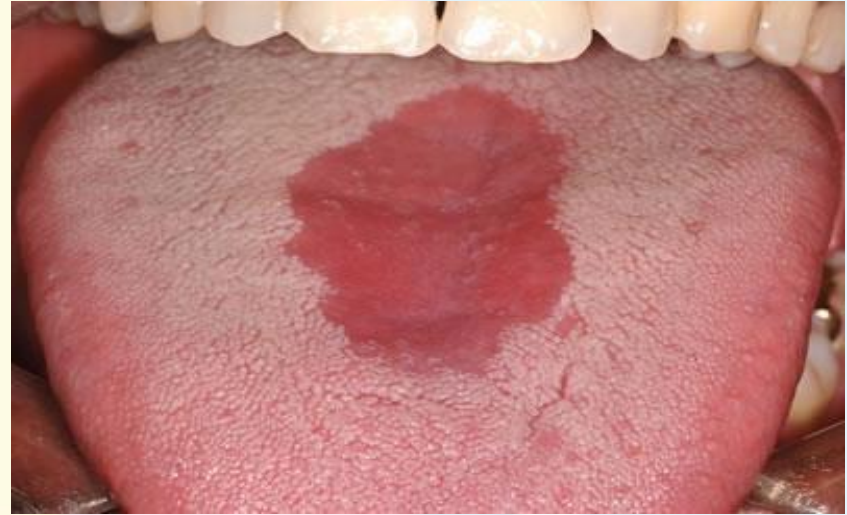
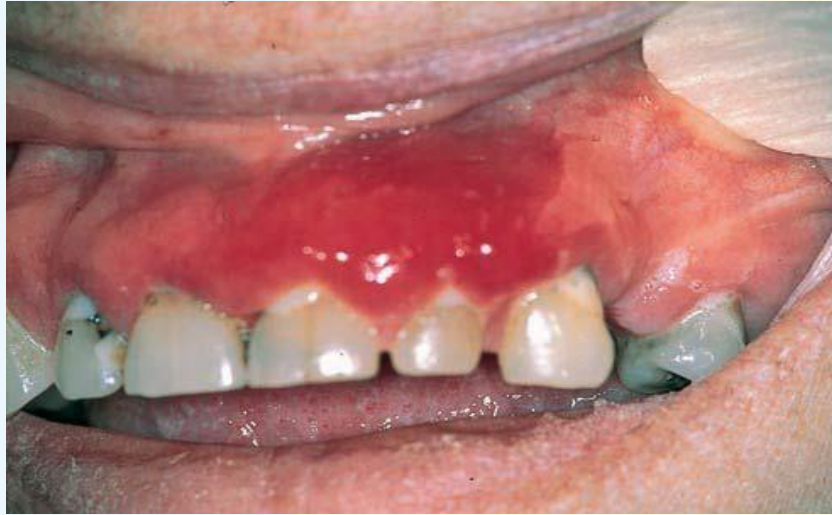# White lesion

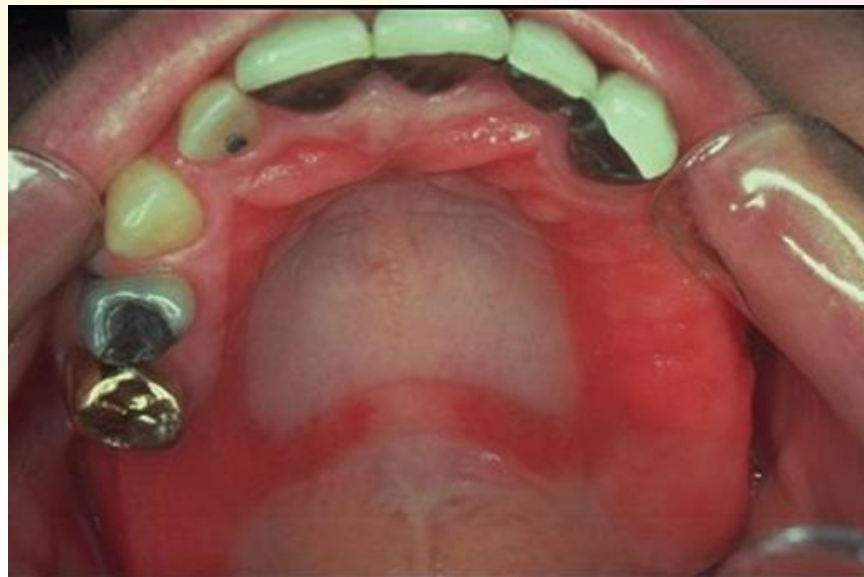
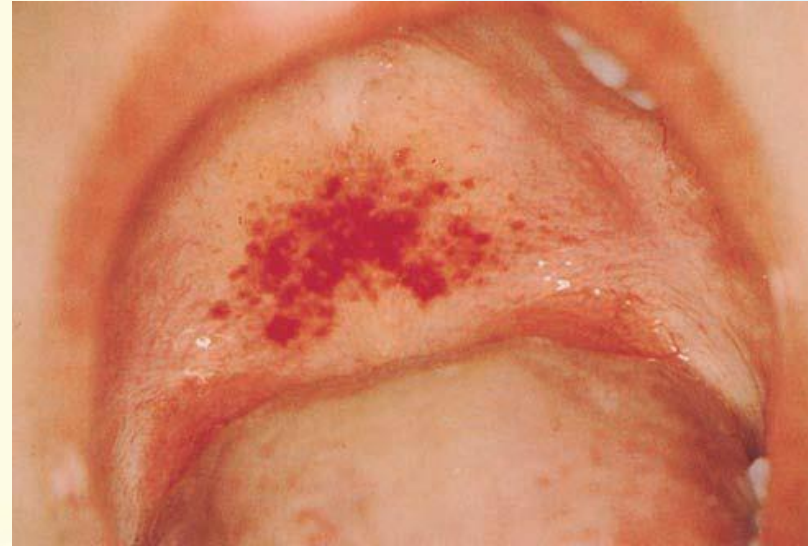
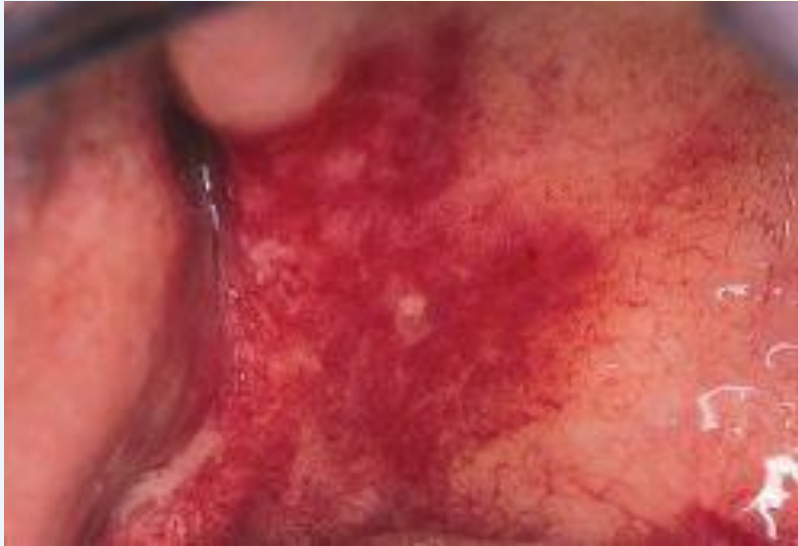

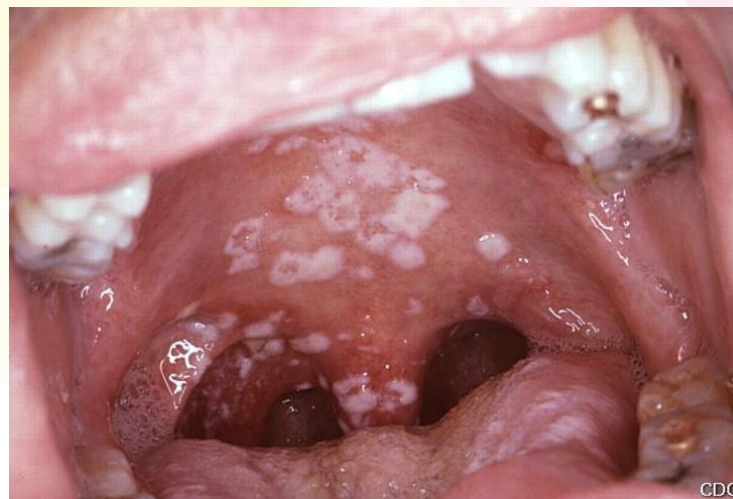
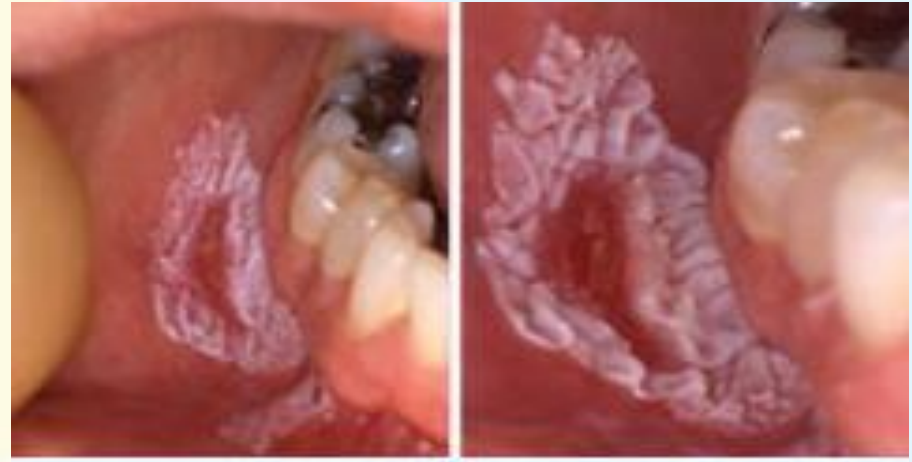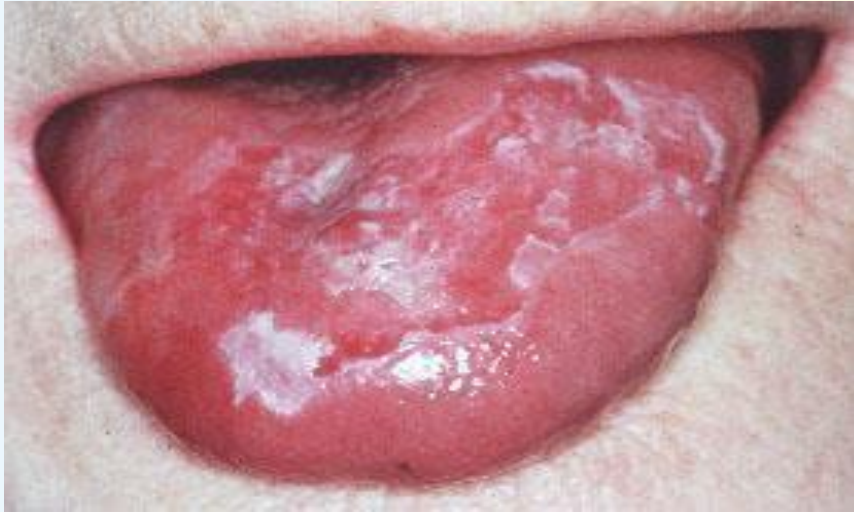# Red lesion



# Red lesion

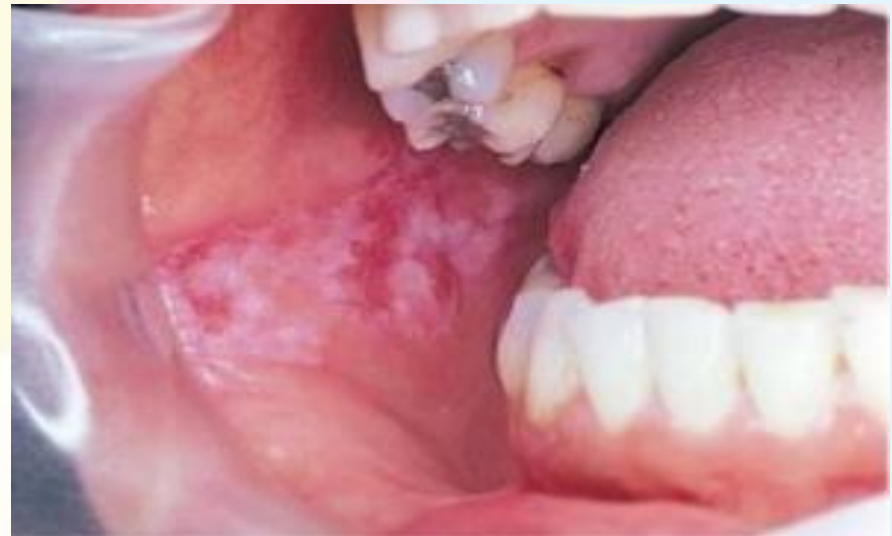
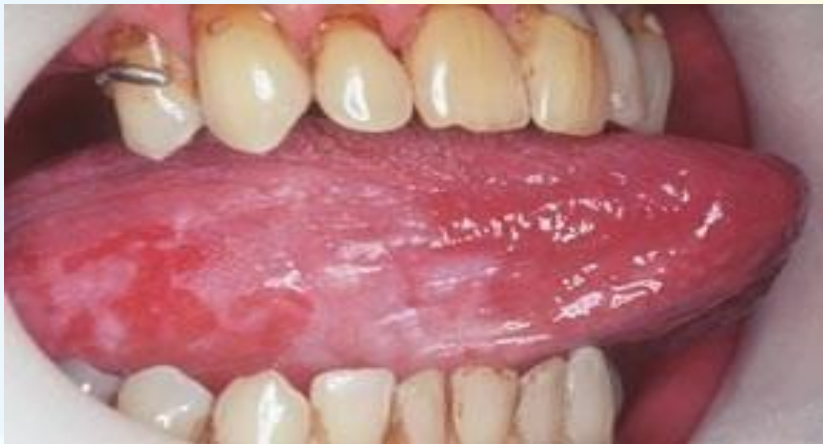
# Red&White lesion

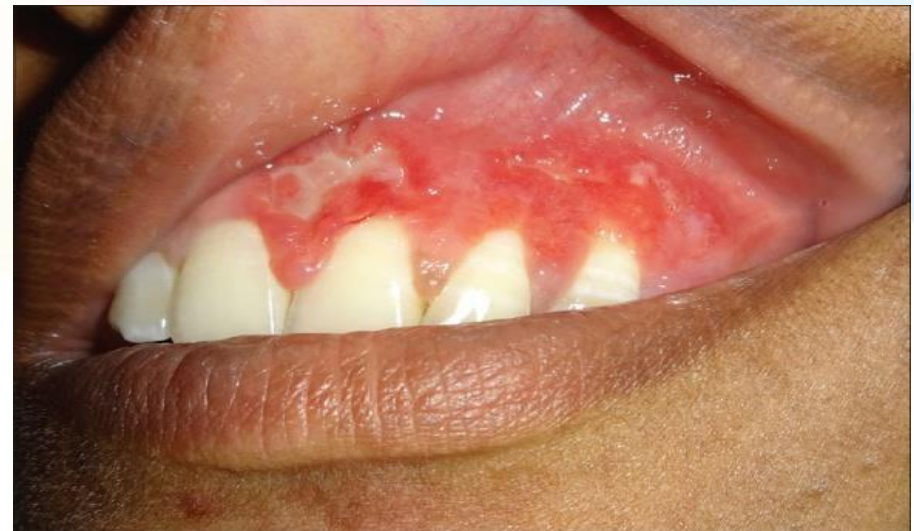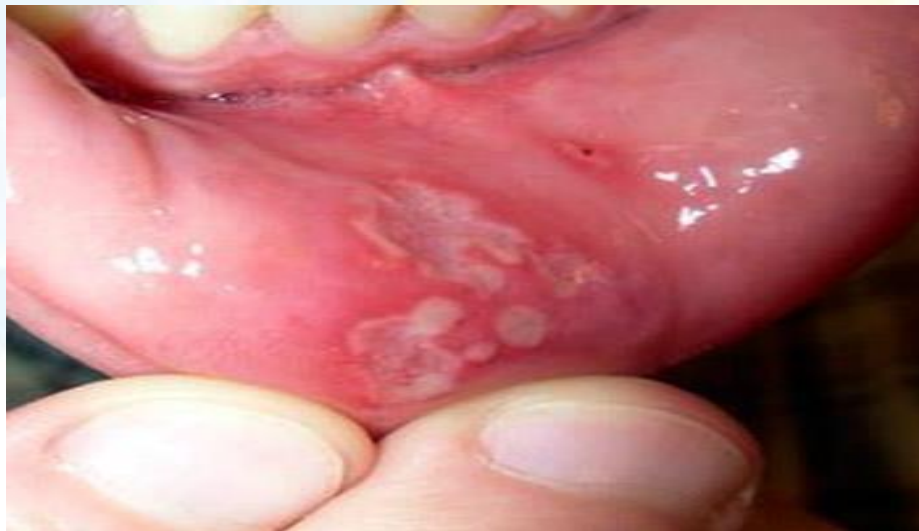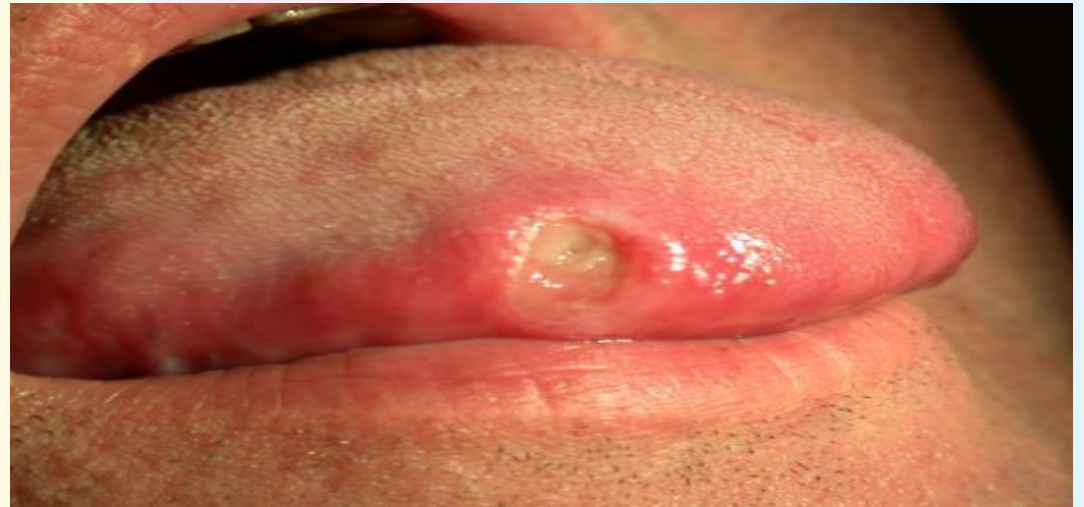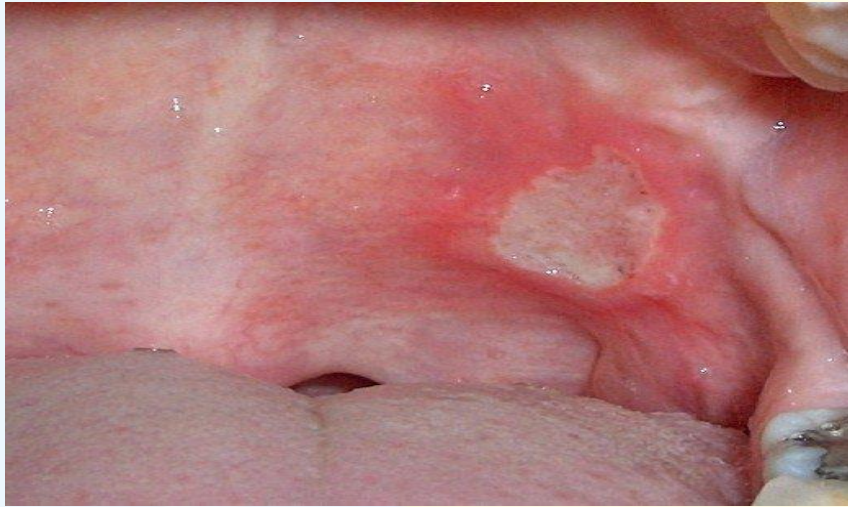




# Red&White lesion

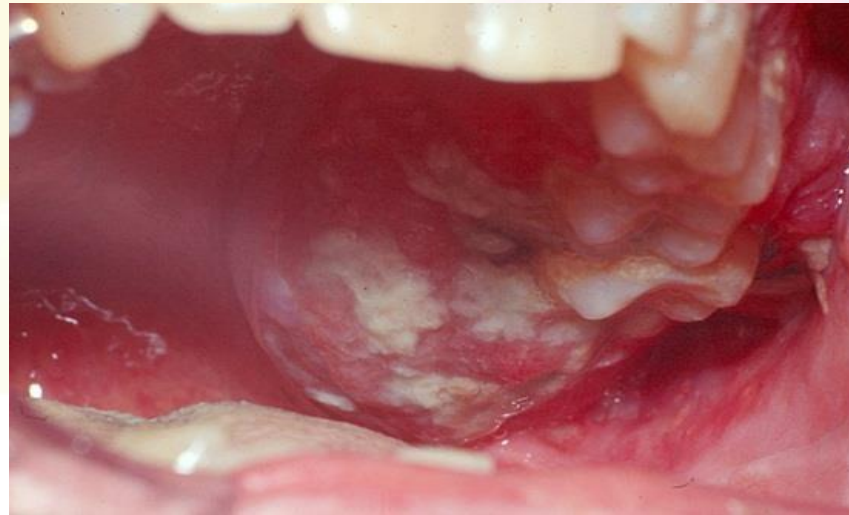
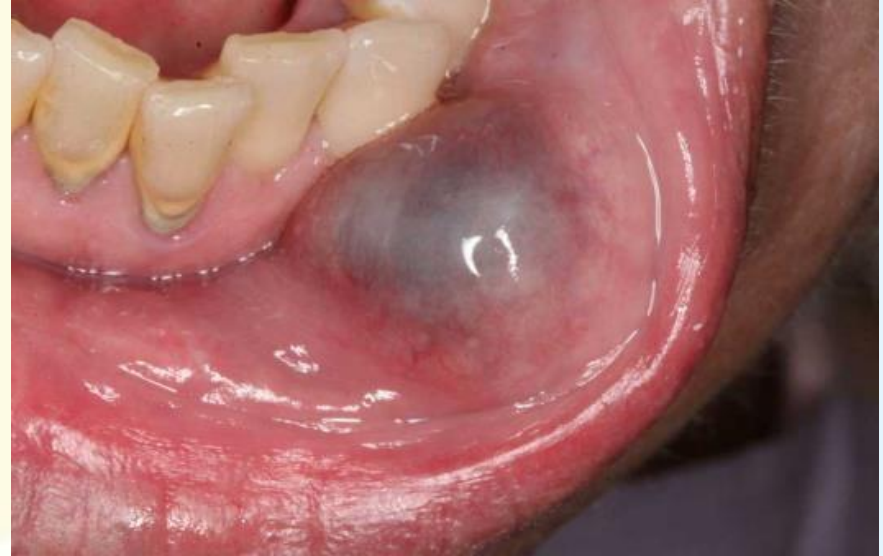
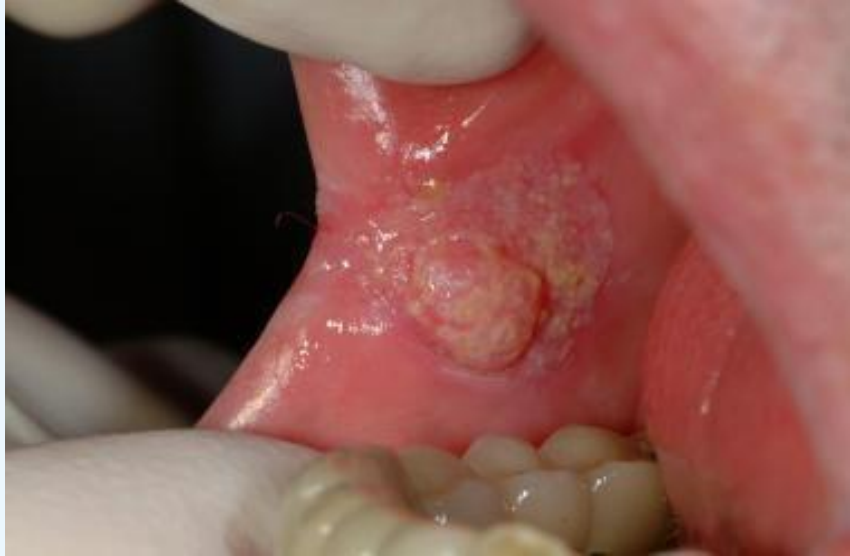# Ulceration

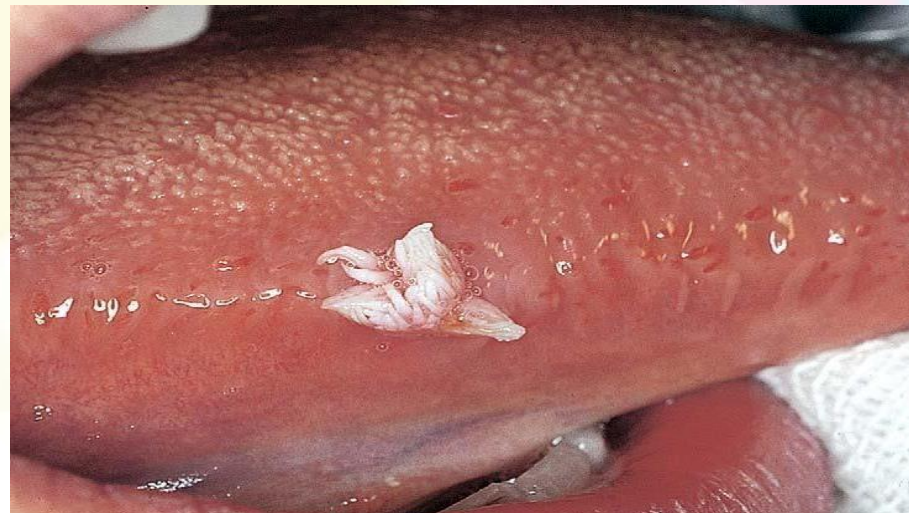
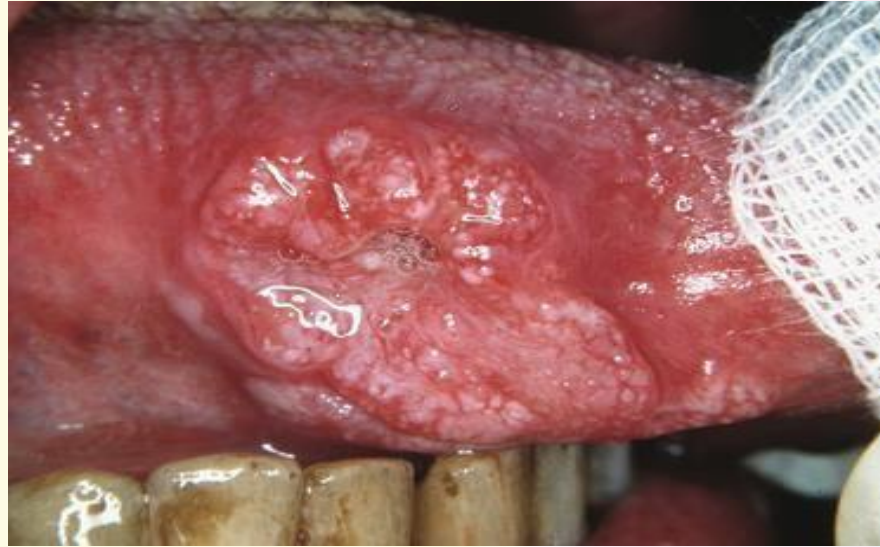


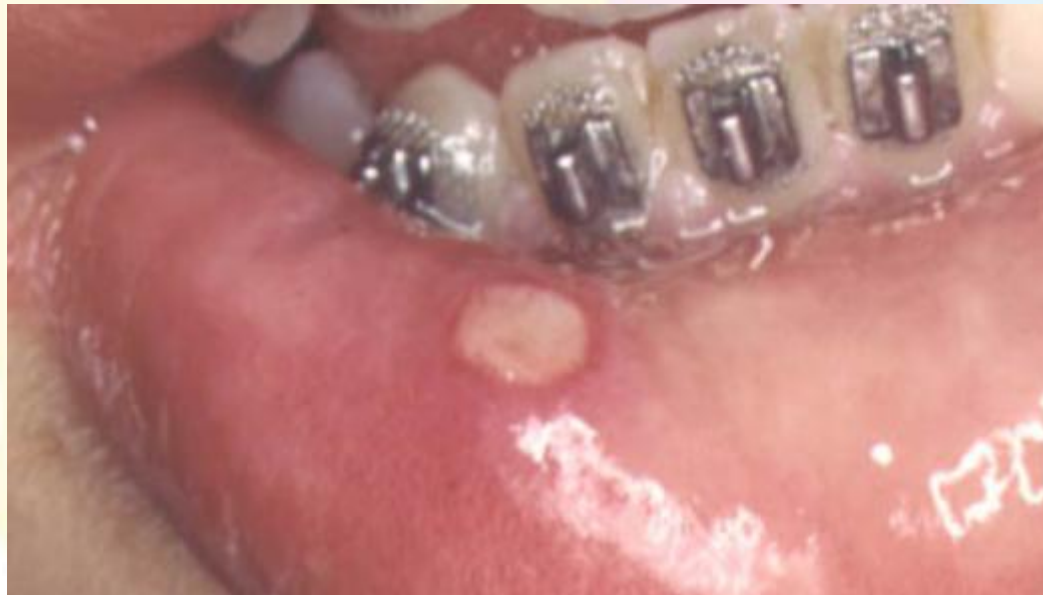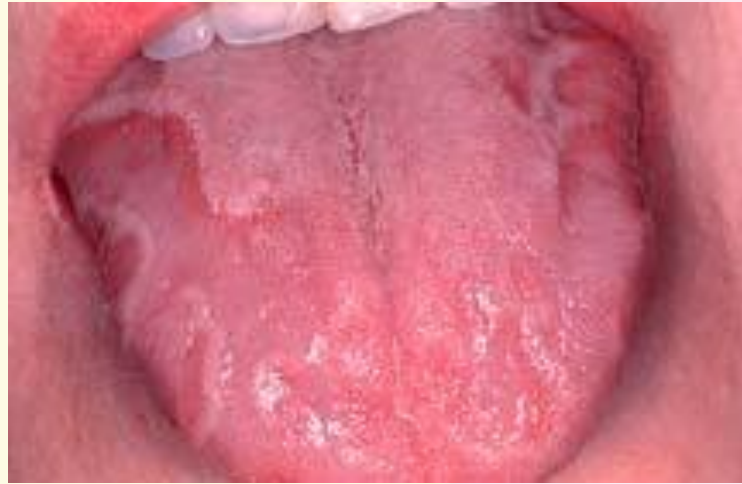# Nodule/mass



# Nodule/mass





**Thank you!**

**Any questions?**